

ward 4B

DR. RAJENDRA PRASAD CENTRE FOR OPHTHALMIC SCIENCES	
UHID: 107043941	Date: 04/11/2023 01:02:18 PM
CR No.: R-046200-23	Ward Name: 4A Bed No: 422
Name: MASTER. AAYANSH RAJ	Unit In-charge: Dr. Radhika Tandon
Age: 1Y7M6D/M	Unit-VI
S/O DEEPAK KUMAR	ACCOUNTS- RS. 21-52371/202324 140
Address: VILL+PO SEKHOPUR VAISHALI 844509 BIHAR	

नेत्र विज्ञान केन्द्र
Centre for Ophthalmic Sciences
स्थान, नई दिल्ली- 110029
Ophthalmic Sciences, New Delhi-110029
CONSULTATION RECORD

एम.आर.-9
M.R.-9

वैवाहिक स्थिति
Marital Status
व्यवसाय
Occupation

कै.पं.सं.
C.R. No.
धर्म
Religion
स्थिति
Status

Referred by Dr. SR ophthal to Dr. SR PHD
Requesting Doctor Consultant & Specially

Findings :

Dear colleague,

Date: 6/11/2023

My pt Mr Aayansh 1y7m / M

Aed :

RE RPE RB + orbital cellulitis

LE WM

Diagnosis or Impression :

Planned:

RE upfront enucleation +
1° implant
↓ GA ↓ MP

NO H/O any
chemo /

focal therapy

Kindly review the case

provide your expert
opinion regarding

clearance for SR

Recommendations:



Consultant's Signature

MANAV SEMA HEALTH AND EDUCATION

6/11/22

Chick SR Paer
Planned for ~~exam~~ emulsion Ina

no clo cough, cold, fever loose stool / 27 /
AIT screen

VitD
Acid
PR-124/m
VRR-38/m
SE-wn

Not in med in Adv
CETC37

- Plan CBC, LFT, KFT
- Emul ~~100/100~~
- dit for 5 & 1 PRK
cleanse

Rash

MANAV SEWA HEALTH AND EDUCATION



Dr. Rajendra Prasad Centre For Ophthalmic Sciences, New Delhi
डॉ राजेंद्र प्रसाद नेत्र विज्ञान केंद्र, नई दिल्ली
भैदानिक रसायन
Clinical Chemistry
अ. भा. आ. स., नई दिल्ली-110029
A.I.I.M.S., New Delhi-110029
रक्त रसायन हेतु / Blood Chemistry

UHD: 167043941
Patient Name: Master. AAYANSHI RAJ
Age: 1 year 7 months 8 days
Unit Name: Unit-VI
Lab Name: Bio Chemistry
Reg Date: 29/09/2023 01:02 PM
Report Generated Date: 06/11/2023 02:38 pm
Recommended By: Dr. PRITA KARMACHARYA
Sex: Male
Sample Received Date: 06/11/2023 10:59 AM
Department: R. P. Centre (Eye Centre)
Unit Incharge: Dr. Radhika Tandon
Lab Sub Centre: RPC OCULAR BIOCHEMISTRY
Sample Collection Date: 06/11/2023 08:35 AM
Dept / IRCH No: 20230650130779
Lab Reference No: 13

Sample Details : RB-061123015

Report

Test Name	Result	Comment	Normal Range
ALK PHOS (ALP)	221		• 240 - 340 I.U
BILIRUBIN (CONJUGATED)	0.05 mg/dL		0.00-0.20
BILIRUBIN (UNCONJUGATED)	0.24		
SGOT (AST)	40 I.U.		0.00-50.00
SGPT (ALT)	16 I.U.		0.00-50.00
CREATININE	0.58 mg/dL		0.50-1.80
POTASSIUM	4.5 mEq/L		3.50-5.00
SODIUM	136 mEq/L		130.00-149.00
UREA	18 mg/dL		10.00-50.00
URIC ACID	3.2 mg/dL		2.00-7.40
TOTAL BILIRUBIN	0.29 mg/dL		0.30-1.20
CHLORIDE	103 mEq/L		101.00-109.00

Over All Comment :

Authorised Signatory

Verified By
deepali

MANAV SEWA HEALTH AND EDUCATION

ब. रो. वि. कार्ड
O.P.D. Card

VI RB-314/23

अनुभाग व दिन
Section and Day II
बुधवार व शनिवार
Wednesday & Saturday

कमरा नंबर
Cabin No.

R. F. Centre (Eye Centre)

UHID: 107043941 Date: 04/10/2023 General

Dept No: 20230050130779 1Y/M RPC OPD-Dr. SR/JR TO


AAVANSH RAJ UNDER UNIT-II R-5A

S/O: DEEPAK KUMAR Unit-II WED, SAT

Room No.: 5A

Address: VILL+PO SEKHOPUR, VAISHALI, BIHAR, Pin: 844309, INDIA

Mobile: 8298298201



यु
ge पता
Address

दिनांक DATE	निदान DIAGNOSIS
----------------	--------------------

उपचार Treatment

4/10/23

CyPR SR M in oncology clinic

Lid edema (+)
Cherry (+)

Cornea not visible.

lyo. r
in surgery

(R) RB r

→ (R) ~~RB r~~ RB r orbital
cells.

(143)

कृपया इस कार्ड को सुरक्षित रखें तथा अस्पताल में दिखाने के समय हर वक्त साथ लायें।

Kindly keep this Card safely and bring it on your follow-up visits.

- धूम्रपान निषेध 2. कूड़ा कर्कट केवल कूड़ेदान में ही डालें 3. थूकिये नहीं
1. No Smoking 2. Use Dustbin 3. No Spitting



Dr. Rajendra Prasad Centre For Ophthalmic Sciences
 ALL INDIA INSTITUTE OF MEDICAL SCIENCES (AIIMS), New Delhi, 110029
 Discharge Report
 PROVISIONAL DISCHARGE CERTIFICATE

PR
 laminated 46
 23/11/23
 7/11/23

UHID : 107043941
 Name: Master AAYANSH RAJ
 Age/Sex: 1 year 7 mons 9 days / Male
 Ward Name: 4A
 Address: VILL+PO SEKHOPUR, VAISHALI, BIHAR, Pin:844509, INDIA
 Noble No: 8298298201
 Date of Admission: 04/11/2023 01:02:18 PM
 Date of Discharge: 08/11/2023 03:41:00 PM
 Cr No: R-046206-23
 Department: R. P. Centre (Fyn Centre)
 Unit: Unit-VI
 Bed No.: 422
 Drug Allergy, if any :- []

ICD Code: ,C69.2
 ICD Description: Malignant neoplasm Retina

Diagnosis
 .RE GROUP E RB ORBITAL CELLULITIS
 LE WNL

Investigation
 Systemic NO SI
 Ocular
 VN
 RE DOES NOT FOLLOW LIGHT
 LE FOLLOWS LIGHT
 IOP
 RE DIG LOW
 LE DIG NORMAL

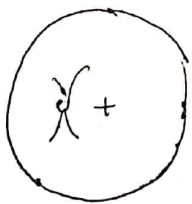
Treatment/Operative Procedure
 Surgeon .DR SHIVANI
 Date 07/11/2023
 Surgery
 .RE PRIMARY ENUCLEATION PRIMARY IMPLANT UNDER GA UNDER NVP ON STUMP 17MM IMPLANT 20MM PMMA
 EUA OF LE : WNL, NO MASS DETECTED

Condition at Discharge
 Vision .RE enucleated
 Anterior Seg. .RE enucleated
 IOP .RE enucleated
 Posterior Seg. .RE enucleated
 .RE echy mottled
 .RE anaphy sutures
 intact, conform in situ

Advice During Discharge
 Oral
 SYP IBUGESIC 6ML (125MG/5ML) PO BD FOR 3 DAYS THEN SOS
 SYP AUGMENTIN 3M (225MG/5ML) TDS FOR 5 DAYS
 SYP CELUSIL TSP BD
 Topical
 RE
 E/D HOXI-D 4T/D
 E/D REFRESH-TEARS 6T/D
 E/D OCCUPO-LA TDS
 Position
 0-0-0
 142B from ocular pathology 7th floor

MANAVS VA HEALTH AND EDUCATION

EUA SR Unit - 6



NO mass detected

Prepared By: Dr. Kritika Raj...

Signature of Senior Resident

Date & Time

Signature of Senior Resident
 Dr. P.P. Centre for Ophthalmic Sciences
 All India Institute of Medical Sciences, New Delhi

8/11/23

E2

Preop
VER

NSRS

9.2 uV 124 msec

W n cardiac γ NO + fixing
6/48 @ 50 cm

(R) USG for PSE = Whole globe filled \bar{z}
mild/mod spikes
ELO VIVE
 \bar{z} calcification seen
not very cooperative

(L) AL = 22.29 mm

stapling EVA DR Deep IDR Ananya

(R) As: congested conjunctiva
corneal edema
cataractous lens
(partially absorbed)

Ac shallow
Rubeosis iridis
ectropion uvea
MS

UBM: mass touching CB, intumescent ballooned
lem = shallow Ac
indolenticular adhesions

(L)
AS WM
lens clear



20110/2023
NRC discussion of MRI dated 15/10/23

(R) tumour large
(R) ON not involved
cellulitis \oplus
No EO spread

डॉ. राजेंद्र प्रसाद नेत्र विज्ञान केंद्र

अखिल भारतीय आयुर्विज्ञान संस्थान

रोगियों के लिए ऑपरेशन के बाद सामान्य निर्देश

1. ऑपरेशन की गई आँख को छूने से पहले अपने हाथों को साबुन और पानी से अच्छी तरह धो लें।
2. ऑपरेशन की गई आँख को साफ जीवाणुहीन रुई अथवा रुमाल से गुनगुने पानी में भिगोकर पानी को पहले उबालकर ठंडा करें, फिर रुई/रुमाल को उसमें निचोड़कर प्रयोग करें) दिन में 2 बार साफ करें।
3. चिकित्सक की सलाह के अनुसार नेत्र औपधि को आराम से आँख की निचली पलक को खींचकर डालें। अपनी नेत्र औपधि की शीशी का ढक्कन लगाएं तथा ठंडी, सूखी एवं साफ जगह में रखें।
4. दो नेत्र औपधियों को आँख में डालने के बीच 5 मिनट का अंतराल रखें।
5. ऑपरेशन की गई आँख को मले नहीं, हल्की असुविधा अथवा शुष्क नेत्र की समस्या होना आम बात है।
6. ऑपरेशन के बाद कम से कम एक सप्ताह तक बाहर जाते समय काले चश्मे का प्रयोग करें। अपने चश्मे को साफ रखें।
7. नहाते समय सावधानी बरतें। नहाते समय पानी आँखों में न जाने पाए। सिर धोते समय किसी अन्य की सहायता से सिर को हल्के से पीछे की ओर झुकाते हुए धोएँ।
8. हल्के घरेलू कार्य करना जारी रखें। अपने चिकित्सक की सलाह एवं निर्देश के अनुसार थोड़ी देर तक पढ़ाई, टेलीविजन देखने जैसे कार्य कर सकते हैं।
9. ऑपरेशन के बाद 2-3 हफ्ते तक रसोई संबंधी कार्य, जिम संबंधी व्यायाम, वजन उठाना, आगे की ओर झुकने संबंधी कार्य, पालतू पशुओं तथा छोटे बच्चों के साथ न खेलें।
10. अधिक दर्द होने, आँखों में लाली, आँखों से अत्यधिक डिस्चार्ज/पानी आना, अचानक दृष्टि में कमी, ऑपरेशन की गई आँख से कम दिखाई देना जैसे लक्षण होने पर नेत्र आपातकालीन विभाग या अपने चिकित्सक से तुरंत संपर्क करें।
11. अपने चिकित्सक द्वारा दिये गए विशेष निर्देशों का पालन करें तथा अस्पताल से छुट्टी के समय निर्दिष्ट सलाह के अनुसार अनुवर्ती जांच के लिए अवश्य आएं।
12. शौचालय में अधिक समय न लगाएँ। कब्ज से बचने कि लिए नियमित आहार लें।

अनुवर्ती चिकित्सा हेतु नियोजित समय प्राप्त किया जा सकता है।

काउंटर नंबर 9, डॉ. राजेंद्र प्रसाद नेत्र विज्ञान केंद्र, ओ. पी. डी.

- एम्स वेब पोर्टल : www.aiims.edu
- IVRS-011-26589999
- कॉल सेंटर - 011-26589142

हम आपके शीघ्र स्वास्थ्य की कामना करते हैं।

प्रशासन,

डॉ. रा. प्र. केंद्र

DR. RAJENDRA PRASAD CENTRE FOR OPHTHALMIC SCIENCES
ALL INDIA INSTITUTE OF MEDICAL SCIENCES

GENERAL POST OPERATIVE INSTRUCTIONS FOR PATIENTS

1. Wash your hands with soap and water before touching the operated eye
2. Clean the operated eye with fresh sterile cotton swab or clean cotton swab / handkerchief soaked in lukewarm water (It should be first boiled, cooled to normal temperature, squeezed and then used) - 2 times a Day.
3. Instill eye drops as advised by gently pulling your lower eyelid. Recap your eye drop and store in a cool, dry and clean place.
4. Gap of 5 minutes to be given between two eye drops.
5. Do not rub the operated eye, Mild discomfort or foreign particle sensation is common.
6. Use tinted glasses for at least 1 week after the surgery while going out and if needed at home. Keep your glasses clean.
7. Precautions to be taken while taking bath. Water should not enter the eyes. Head bath can be taken with head gently tilted backwards with help from someone.
8. Light household activities can be continued. Light reading, watching television is permitted until instructed otherwise by your doctor.
9. Avoid Kitchen work, gym, exercise, weight lifting, forward bending, playing with pets and small children for 2-3 weeks after surgery.
10. In case of severe pain, redness of eyes, excess of discharge/ watering, sudden loss of vision, low vision in operated eye, immediately contact your treating doctor or Eye Casualty.
11. Kindly follow the special instructions given by your treating doctor and come for follow -up as advised at the time of discharge.
12. Do not strain in washroom. Have regular diet to avoid constipation.

Follow up Appointment can be taken from:

- Counter No. 9, Dr. R.P.Centre, OPD
- AIIMS web portal: www.aiims.edu
- IVRS - 011-26589999
- Call Centre-011-26589142

WE WISH YOU A SPEEDY RECOVERY!!

***Administration,
Dr.R.P.Centre***

the lateral, superior and inferior right extra-ocular muscle sand right superior oblique muscle.

Globes are normal in size and signal intensity .

Ocular muscles are normal .

Optic nerves are normal in courser and signal intensity

No e/o any foreign body noted.

No any hemorrhage / collection is seen.


Superior & inferior orbital fissures and optic foramina are normal.

Chiasm and pituitary gland are normal.

IMPRESSION:

T2 hypointense lesion is noted involving the posterior chamber of right orbit, mild heterogenous post-contrast enhancement is noted, there is hyperintensity noted involving the lateral, superior and inferior right extra-ocular muscle sand right superior oblique muscles -- ? Neoplastic.

Recommended clinical correlation.



DR. DEEPAK TOMAR
MBBS, MD, (Radiodiagnosis)
Consltant Radiologist



Scan QR to download report

Name	AAYANSH 18M/M	Age	018Y - M
Date	15/10/2023	Patient Id	23101474
Referring Doctor		Center	C15 MRI IMAGING AND DIAGNOSTIS RESEARCH CENTRE LTD. NEW DELHI

CEMRI BRAIN

The study reveals:

Bilateral cerebral hemispheres are normal in signal intensity and morphology. No focal lesion seen. No evidence of any restricted diffusion on DWI or blooming on GRE images could be noted. Grey white matter differentiation is well maintained. Myelination pattern is grossly normal.

Bilateral basal ganglia and thalami appear normal in morphology and signal intensity.

Brainstem, bilateral cerebellum are normal.

Supratentorial ventricular system is normal.

Fourth ventricle is midline in position and is normal in size.

Major intra-cranial venous sinuses show normal flow void.

No extra axial collection seen.

IMPRESSION:- CEMRI brain reveals no significant abnormality.

Suggested: Clinical correlation.

**DR. DEEPAK TOMAR
MBBS, MD
CONSULTANT RADIOLOGY**

CEMRI ORBIT

Findings:

T2 hypointense lesion is noted involving the posterior chamber of right orbit, mild heterogenous post-contrast enhancement is noted, there is hyperintensity noted involving

GST INVOICE



National Society for the Prevention of Blindness
 Dr. Rajendra Prasad Centre for Ophthalmic Sciences,
 Ansari Nagar AIIMS, New Delhi-110029
 Contact : 011-26588500/ 700 Extn-3018
 GSTIN/UIN: 07AAATN0455C1Z1
 State Name : Delhi, Code : 07

Invoice No. "7022	Dated 1-Jan-24
Delivery Note	
Reference No. & Date. dt. 1-Jan-24	Other References
Buyer's Order No.	Dated
Dispatch Doc No.	Delivery Note Date
Dispatched through	Destination

Buyer (Bill to)
AYAUSH
 State Name : Delhi, Code : 07

SI No.	Description of Goods	Quantity	Rate (Incl. of Tax)	Rate	per	Disc. %	Amount
1	ARTIFICIAL EYES	1.00 Pcs	349.44	312.00	Pcs		312.00
	CGST @ 6%						19.00
	SGST @ 6%						19.00
Total		1.00 Pcs					₹ 350.00

Amount Chargeable (in words) E. & O.E
INR Three Hundred Fifty Only

	Taxable Value	CGST		SGST/UTGST		Total Tax Amount
		Rate	Amount	Rate	Amount	
	312.00	6%	19.00	6%	19.00	38.00
Total:	312.00		19.00		19.00	38.00


Tax Amount (in words) : **INR Thirty Eight Only**

Company's PAN : **AAATN0445C**

Declaration

We declare that this invoice shows the actual price of the goods described and that all particulars are true and correct.

for National Society for the Prevention of Blindness



This is a Computer Generated Invoice



Histopathology Report

Ocular Pathology

Dr. Rajendra Prasad Centre for Ophthalmic Sciences

All India Institute of Medical Sciences

Ansari Nagar, New Delhi - 110029, India

Name of the Patient: Ayansh

Lab Reference No. : 23-1546

Age : 1 Years Sex : Male

Received on : 7/11/2023

UHID No. : 107043941

Date of Report : 15/11/2023

Bed No. : 422

Unit Incharge : Prof. Tandon

Nature of the Material Enucleation.
Submitted :

Report :

- Enucleated right eyeball
- Poorly differentiated retinoblastoma
- The tumor shows extensive necrosis (LTD 20.6 mm)
- Choroid shows oedema.
- All Ocular structures including iris, ciliary body, choroid and optic nerve including its resected margin are free of tumor.

ATCC-PT, NOMO

S. Sen

Reported By

Consultant :

Dr. SEEMA SEN
Prof. & Officer-in-charge
Ocular Pathology
Dr. R.P. Centre, AIIMS
New Delhi-110029



अ० भा० आ० सं० अस्पताल / A.I.I.M.S. HOSPITAL
बहिरंग रोगी विभाग / Out Patient Department

अस्पताल के अन्दर धूमपान मना है। SMOKING IS PROHIBITED IN HOSPITAL PREMISES



बाल चिकित्सा विभाग



UHID: 107043941
Dept No.: 20230030030483

कमरा / Room

C-207
Unit-III

Paediatric

य०रो०यि० पंजीकृत सं०/O.P.I

बुध,शनि.

आयु
Age

Wed.Sat(बुध,शनि)
21/10/2023

Queue: N27



Reporting 09 58 16

LC2110231715 107043941

LH2110231185 107043941

AAYANSHRAJ

AAYANSH RAJ

S/O DEEPAK KUMAR

1Y6M 23D / M (पुरुष)

Add : VILL-PO SEKHOPUR VASHALI BHAR. Pin 844509,

INDIA

Mob: 8298298201 New Patient General 0

निदान/Diagnosis

दिनांक/Date

49

उपचार/Treatment

Ⓡ gpe — 1 comb.

Man.

Acetone

ESC

WATER

Viral make

COY

Monon

N/V

Weg

2 film

Disin on Th

Mark Chem

25/10



CLEAN AND GREEN AIIMS / एम्स का यही संकल्प, स्वच्छता से काया कल्प

अंगदान-जीवन का बहुमूल्य उपहार / ORGAN DONATION - A GIFT OF LIFE

O.R.B.O., AIIMS, 26588360, 26593444, www.orbo.org Helpline - 1060 (24 hrs service)



My Hospital
meraaspatal.nhp.gov.in

ब० रो० वि० कार्ड
O.P.D. Card

डा० राजेन्द्र प्रसाद नेत्र विज्ञान केन्द्र
अ० भा० आयु० सं०, नई दिल्ली - 110029

Dr. Rajendra Prasad Centre for Ophthalmic Sciences
A.I.I.M.S., New Delhi-110029

यू०एच०आई०डी० संख्या
UHID No.



अनुभाग व दिन Section and Day VI बुधवार व शनिवार Wednesday & Saturday

कमरा नंबर
Cabin No.

आचार्य राधिका टंडन का एकक
Prof. Radhika Tandon's Unit

रोगी का नाम Name of the Patient	पुत्र/पुत्री/पत्नी S/D/W	लिंग Sex	आयु Age	पता Address
Ayansu		M	17	

दिनांक DATE	निदान DIAGNOSIS
----------------	--------------------

6/2/24


उपचार Treatment
LVA done ↓ 11/1/24 - (Prof. Bhavana/D. Manu)
Dr. Sreepa

(R) enucleated
(L) WNL

HPE - No HRF

chemo/IAE ⊕
CBRT ⊕

OS



MANAV SEWA HEALTH AND EDUCATION

कृपया इस कार्ड को सुरक्षित रखें तथा अस्पताल में दिखाने के समय हर वक्त साथ लायें।

Kindly keep this Card safely and bring it on your follow-up visits.

- धूम्रपान निषेध
- कूड़ा कर्कट केवल कूड़ेदान में ही डालें
- थूकिये नहीं
- No Smoking
- Use Dustbin
- No Spitting

दिनांक - Date

उपचार - Treatment

D/F.
CWA after 3 months
28/5/23
R.No 63
6:00AM

NPD - 8 hrs slides
- 6 hrs processed milk
- 4 hrs breast milk
- 2 hrs water

MANAV SEWA HEALTH AND EDUCATION

नेत्र ईश्वरीय सर्वश्रेष्ठ उपहार है जिनका मनुष्य जीवन में दान करना परमश्रेष्ठ है।

इनकी पूर्ण रक्षा कीजिए ताकि ये आपकी रक्षा कर सकें।

Eyes are God's most precious gift to man kind and eye donation is the most noble deed.

Take full care of them so that they can take care of you.

WWW.Swavlamban Card. gov.in (U.D.D CARD)

ब० रो० वि० कार्ड
O.P.D. Card

डा० राजेन्द्र प्रसाद नेत्र विज्ञान केन्द्र
अ० भा० आयु० सं०, नई दिल्ली - 110029

Dr. Rajendra Prasad Centre for Ophthalmic Sciences
A.I.I.M.S., New Delhi-110029

यू०एच०आई०डी० संख्या
UHID No.



अनुभाग व दिन
Section and Day VI
बुधवार व शनिवार
Wednesday & Saturday

कमरा नंबर
Cabin No.

आचार्य राधिका टंडन का एकक
Prof. Radhika Tandon's Unit

रोगी का नाम Name of the Patient	पुत्र/पुत्री/पत्नी S/D/W	लिंग Sex	आयु Age	पता Address
Ayansh				
दिनांक DATE	निदान DIAGNOSIS			

30/12/23

उपचार Treatment

Ref to H.S.
to hand
certific
[Signature]

कृपया इस कार्ड को सुरक्षित रखें तथा अस्पताल में दिखाने के समय हर वक्त साथ लायें।

Kindly keep this Card safely and bring it on your follow-up visits.

1. धूम्रपान निषेध
2. कूड़ा कर्कट केवल कूड़ेदान में ही डालें
3. थूकिये नहीं
1. No Smoking
2. Use Dustbin
3. No Spitting

दिनांक - Date

उपचार - Treatment

Ado

Syn Osmacolic 4ml $\xrightarrow{1ml}$ (6) $\xrightarrow{1ml}$ (5) $\xrightarrow{1ml}$ (4) $\xrightarrow{1ml}$ (3) $\xrightarrow{1ml}$ (2) $\xrightarrow{1ml}$ (1)

Syn. gelatin 1 tsp BD.

(R) | Ed moni D (3) $\xrightarrow{1ml}$ (2) $\xrightarrow{1ml}$ (1) $\xrightarrow{1ml}$ (1)

Ed rephur team (4)

Hu dhu buellu/0's 142B. ifse.

(R) prosthetic fitting =

cont-ed. cmc 0.5% (3)
R/E

Payant
FU on Monday - VNO, 24

Oculonoma di
Rgth PRC / cont 7
|
on

for Sibling
Screening

नेत्र ईश्वरीय सर्वश्रेष्ठ उपहार है जिनका मनुष्य जीवन में दान करना परमश्रेष्ठ है।
इनकी पूर्ण रक्षा कीजिए ताकि ये आपकी रक्षा कर सकें।

Eyes are God's most precious gift to man kind and eye donation is the most noble deed.
Take full care of them so that they can take care of you.

ब० रो० वि० कार्ड
O.P.D. Card

डा० राजेन्द्र प्रसाद नेत्र विज्ञान केन्द्र
अ० भा० आयु० सं०, नई दिल्ली - 110029

Dr. Rajendra Prasad Centre for Ophthalmic Sciences
A.I.I.M.S., New Delhi-110029

यू०एच०आई०डी० संख्या
UHID No.



अनुभाग व दिन
Section and Day VI
बुधवार व शनिवार
Wednesday & Saturday

कमरा नंबर
Cabin No.

आचार्य राधिका टंडन का एकक
Prof. Radhika Tandon's Unit

रोगी का नाम Name of the Patient	पुत्र/पुत्री/पत्नी S/D/W	लिंग Sex	आयु Age	पता Address
Ayush		M	14	
दिनांक DATE	निदान DIAGNOSIS			

उपचार Treatment

15/11/23

CSF Ophthalmology clinic

(R) enucleated for group E. (7/11/23)
E. coli

HPE-

grossly
diffuse

tumor necrosis,

no HRF

(L) WML

DH EUA - 6/2/2024.

casualty of 63

NPO - 6hs - solids
6hs - Benartmin
2ms - milk

कृपया इस कार्ड को सुरक्षित रखें तथा अस्पताल में दिखाने के समय हर वक्त साथ लायें।

Kindly keep this Card safely and bring it on your follow-up visits.

- धूम्रपान निषेध
- कूड़ा कर्कट केवल कूड़ेदान में ही डालें
- थूकिये नहीं
1. No Smoking
2. Use Dustbin
3. No Spitting

दिनांक - Date

उपचार - Treatment

Ⓡ USG sb Intraocular Mass &
Intraocular Calcification sb RB

Adv Syp. Augmentin (225ml) 1.5ml TDS
Syp. PCM (125mg/ml) 5ml BD } x 7 days

Ⓡ Eye Refresh tears
Old Myia Ⓢ

Review & films on Monday, Ward 4A, 10am
for NRC

Flu tomorrow in ward (4A) (9AM) ^{not} CR/6.
Dr Bahubali.

Child has not passed stools since last 3 days

Urgent Paeds Emergency opinion

~~5/1/23~~ lower lid abscess @ ~~Chit S~~ Chit S Opinion.

नेत्र ईश्वरीय सर्वश्रेष्ठ उपहार है जिनका मनुष्य जीवन में दान करना परमश्रेष्ठ है।
इनकी पूर्ण रक्षा कीजिए ताकि ये आपकी रक्षा कर सकें।

Eyes are God's most precious gift to man kind and eye donation is the most noble deed.
Take full care of them so that they can take care of you.



नकदी रसीद / CASH RECEIPT
अखिल भारतीय आयुर्विज्ञान संस्थान / ALL INDIA INSTITUTE OF MEDICAL SCIENCES
अखिल भारतीय आयुर्विज्ञान संस्थान, नई दिल्ली
आसानी नगर, नई दिल्ली-110029, Asha Nagar, New Delhi-110029
ALL INDIA INSTITUTE OF MEDICAL SCIENCES (AIIMS)
New Delhi,

दूरभाष { 26588500
Phones { 26588700

रसीद संख्या / Receipt No.:

New Delhi,

दिनांक / Dated :

जमाकर्ता / Received From:

नियुक्ति पर्ची

रोगी प्रकार / Patient Type :

ओ.पी.डी./यू.एच.आई.डी. सं / OPD/ UHID No.

कक्ष संख्या

के नाम By ACCOUNT OF ANANDANA DEO SWSC (New)

General ₹ 0.0

Print Appointment Slip

Department Name: Paediatrics/Paediatric

Appointment Date: 15/11/2023

Reporting Time: 9:00 AM-10:00 AM

Doctor Name Dr. RACHNA SETH

Appointment Request date

20/10/2023

Name of Patient

MASTER. AAYANSH RAJ

Appointment No

2023102010716

Sex

Male

Age

1 year 6 months 22 days

Contact Details

Mobile: XXXXX201

Request Mode

counter

Queue No:

N5

Remarks:

Your UHID Is : 107043941.

भुगतान का प्रकार / Payment Mode :

रुपये / INR (Rs.):

रुपये शब्दों में / Rs. in Words

यह कम्प्यूटर द्वारा जारी की गई रसीद है और इसमें हस्ताक्षर और मोहर अपेक्षित नहीं है।
THIS IS COMPUTER GENERATED SLIP AND DOES NOT REQUIRE SIGNATURE AND STAMP



नगदी रसीद / CASH RECEIPT
 अखिल भारतीय आयुर्विज्ञान संस्थान / All India Institute of Medical Sciences
 अन्सारी नगर, नई दिल्ली-110029 / Ansari Nagar, New Delhi - 110029
 डॉ० राजेन्द्र प्रसाद नेत्र विज्ञान केन्द्र / Dr. Rajendra Prasad Centre for Ophthalmic Sciences
 दूरभाष / Phones : 26593012, 26593115



Dept No: 20230030030483

Receipt No.:

Received From:

OPD/MRD No.:

ON ACCOUNT OF

ACCOUNTS-21/52571/202324 |Original|RPC

Receipts

MASTER. AAYANSH RAJ, Age :1 Yrs 7 Mons 6 Days

107043941 (OPD)



Dated :

Patient Type :

Room No. :

04/11/2023

General

Sl No.	Service Name	Amount
1	ADVANCE - RPC LONG ADMISSION FOR GENERAL 4 DAY	140.00
2	OTHER CHARGES (RPC) - ADMISSION CHARGE	25.00

Printed on 04 Nov 2023 11:01:52 AM

शरीरमाद्यं खलु धर्मसाधनम्

MR.PAWAN KUMAR RPC

Cash

165.00(Including 0.0% GST on room rent only)

Rupees One Hundred and Sixty Five Only

Payment Mode:

INR (Rs.) :

Rs. in Words

दिनांक - Date

उपचार - Treatment

(P)

UBM : man touching
clay body
inherent balloned
len to shallow
Ac - mdo intraculal adhesion

(P)

US G for PSE ↓
lage 1/0 lenton
occupying
entire globe
to calcification

(R)

Pektam
fn G not visible

Rx: continue oral
medication
+
topical med.

Advice

NRC discussion of MRI of (15/10/2023)

Mon ward 4A, 4th floor → done on 20/10/23

New RBC OPD

Refer to Peds oncology
considering systemic

2nd floor for
chemotherapy.

Prof Rachna
Sekh
DR Aditya Gupta
DR Sayash

FU next week for amendment of
orbital cellulitis

old RBC 142 B

Mon Wed 2 PM

₹

नेत्र ईश्वरीय सर्वश्रेष्ठ उपहार है जिनका मनुष्य जीवन में दान करना परमश्रेष्ठ है।
इनकी पूर्ण रक्षा कीजिए ताकि ये आपकी रक्षा कर सकें।

Eyes are God's most precious gift to man kind and eye donation is the most noble deed.
Take full care of them so that they can take care of you.

ब. रो. वि. कार्ड
O.P.D. Card

डा. राजेन्द्र प्रसाद नेत्र विज्ञान केन्द्र
अ. भा. आयु. सं., नई दिल्ली - 110029

Dr. Rajendra Prasad Centre for Ophthalmic Sciences
A.I.I.M.S., New Delhi-110029

यू.एच.आई.डी. संख्या
UHID No. 107043941



अनुभाग व दिन
Section and Day VI
बुधवार व शनिवार
Wednesday & Saturday

कमरा नंबर
Cabin No.

आचार्य राधिका टंडन का एकक
Prof. Radhika Tandon's Unit

रोगी का नाम Name of the Patient	पुत्र/पुत्री/पत्नी S/D/W	लिंग Sex	आयु Age	पता Address
Nayansh Raj		M	17	

दिनांक DATE	निदान DIAGNOSIS
----------------	--------------------

20/10/2023

उपचार Treatment

Staging EVA → DR Peep / DR Ananya

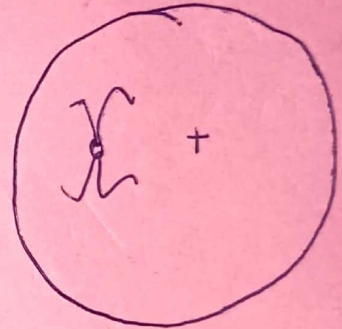
(R)

- AS
- congested conjunctiva
- corneal edema
- cataractous lens
partially absorbed
- AC shallow
- Rubeosis iridis
- echopion uvea (+)
- NMI (+)

(L)

AS WNL
IEM clear

(L)



कृपया इस कार्ड को सुरक्षित रखें तथा अस्पताल में दिखाने के समय हर वक्त साथ लायें।

Kindly keep this Card safely and bring it on your follow-up visits.

- धूम्रपान निषेध
- कूड़ा कर्कट केवल कूड़ेदान में ही डालें
- थूकिये नहीं
- No Smoking
- Use Dustbin
- No Spitting

ब० रो० वि० कार्ड
O.P.D. Card

डा० राजेन्द्र प्रसाद नेत्र विज्ञान केन्द्र
अ० भा० आयु० सं०, नई दिल्ली - 110029

Dr. Rajendra Prasad Centre for Ophthalmic Sciences
A.I.I.M.S., New Delhi-110029



अनुभाग व दिन
Section and Day VI
बुधवार व शनिवार
Wednesday & Saturday

कमरा नंबर
Cabin No.

यू०एच०आई०डी० संख्या
UHID No. 107043941

आचार्य राधिका टंडन का एकक
Prof. Radhika Tandon's Unit

रोगी का नाम Name of the Patient	पुत्र/पुत्री/पत्नी S/D/W	लिंग Sex	आयु Age	पता Address
Aayansh Ray		M	14	
दिनांक DATE	निदान DIAGNOSIS			
5/10/23	उपचार Treatment CLB Dr. Radhika Meel Unit-V			

Advice:
- Scraping of membrane → Seat for bact & fungal ds.

- ~~Coarse coral~~
- CST Coral antibiotic

(R) / - Eto vigamox 2 hrly.
- Eto Ciprox HS.

- Flu ayeu 2 days on Saturday.
8:30 am

कृपया इस कार्ड को सुरक्षित रखें तथा अस्पताल में दिखाने के समय हर वक्त साथ लायें।

Kindly keep this Card safely and bring it on your follow-up visits.

1. धूम्रपान निषेध
2. कूड़ा कर्कट केवल कूड़ेदान में ही डालें
3. थूकिये नहीं

1. No Smoking

2. Use Dustbin

3. No Spitting

दिनांक - Date

उपचार - Treatment

C/O/w Dr. Lomi

— continue syb. Augmentin & Pen

— D/F staging evA

20/10/2023

OT #63, Sam

NPO (can solid)
Can water

MANAV SEWA HEALTH AND EDUCATION

नेत्र ईश्वरीय सर्वश्रेष्ठ उपहार है जिनका मनुष्य जीवन में दान करना परमश्रेष्ठ है।

इनकी पूर्ण रक्षा कीजिए ताकि ये आपकी रक्षा कर सकें।

Eyes are God's most precious gift to man kind and eye donation is the most noble deed.

Take full care of them so that they can take care of you.

ब० रो० वि० कार्ड
O.P.D. Card



अनुभाग व दिन
Section and Day VI
बुधवार व शनिवार
Wednesday & Saturday

कमरा नंबर
Cabin No.

डा० राजेन्द्र प्रसाद नेत्र विज्ञान केन्द्र
अ० भा० आयु० सं०, नई दिल्ली - 110029

Dr. Rajendra Prasad Centre for Ophthalmic Sciences
A.I.I.M.S., New Delhi-110029

यू०एच०आई०डी० संख्या

UHID No. 107043945

आचार्य राधिका टंडन का एकक

Prof. Radhika Tandon's Unit

रोगी का नाम Name of the Patient	पुत्र/पुत्री/पत्नी S/D/W	लिंग Sex	आयु Age	पता Address
Ajayansh		M	17	

दिनांक DATE	निदान DIAGNOSIS
16/10/23	उपचार Treatment NRC by Prof. Sanjay Sharma → Unit 6

cat NRC
① - mass 2x2
filling globe
ON involvment
clinically can't connect.
Grp E Pb

① - tumor - large
- ON not involved
- cellulitis ⊕

40 swells ⊕
x 3 days
① - Intraocular mass
① - intraocular calcification

① 142 2pm

कृपया इस कार्ड को सुरक्षित रखें तथा अस्पताल में दिखाने के समय हर वक्त साथ लायें।

Kindly keep this Card safely and bring it on your follow-up visits.

1. धूम्रपान निषेध
2. कूड़ा कर्कट केवल कूड़ेदान में ही डालें
3. थूकिये नहीं

1. No Smoking
2. Use Dustbin
3. No Spitting

ब० रो० वि० कार्ड
O.P.D. Card

डा० राजेन्द्र प्रसाद नेत्र विज्ञान केन्द्र
अ० भा० आयु० सं०, नई दिल्ली - 110029

Dr. Rajendra Prasad Centre for Ophthalmic Sciences
A.I.I.M.S., New Delhi-110029



अनुभाग व दिन
Section and Day VI
बुधवार व शनिवार
Wednesday & Saturday

कमरा नंबर
Cabin No.

यू०एच०आई०डी० संख्या

UHID No. 107043941

आचार्य राधिका टंडन का एकक

Prof. Radhika Tandon's Unit

दिनांक DATE	निदान DIAGNOSIS
20/10/23	उपचार Treatment MRI discussion by SR radiology Radiology
MRI of 15/10/23	Ret on with involvement Intraocular extent only orbital cellulitis ⊕ no Extraocular spread.

कृपया इस कार्ड को सुरक्षित रखें तथा अस्पताल में दिखाने के समय हर वक्त साथ लायें।

Kindly keep this Card safely and bring it on your follow-up visits.

1. धूम्रपान निषेध
2. कूड़ा कर्कट केवल कूड़ेदान में ही डालें
3. थूकिये नहीं
1. No Smoking
2. Use Dustbin
3. No Spitting

ब० रो० वि० कार्ड
O.P.D. Card

डा० राजेन्द्र प्रसाद नेत्र विज्ञान केन्द्र
अ० भा० आयु० सं०, नई दिल्ली - 110029

Dr. Rajendra Prasad Centre for Ophthalmic Sciences
A.I.I.M.S., New Delhi-110029



अनुभाग व दिन
Section and Day VI
बुधवार व शनिवार
Wednesday & Saturday

कमरा नंबर
Cabin No.

यू.एच.आई.डी. संख्या

UHID No. 107043952

आचार्य राधिका टंडन का एकक

Prof. Radhika Tandon's Unit

रोगी का नाम Name of the Patient	पुत्र/पुत्री/पत्नी S/D/W	लिंग Sex	आयु Age	पता Address
Duyanshu		M	6	

दिनांक DATE	निदान DIAGNOSIS
8/1/24	उपचार Treatment OPTOSCOP. (153) Done wvl 15/15

कृपया इस कार्ड को सुरक्षित रखें तथा अस्पताल में दिखाने के समय हर वक्त साथ लायें।

Kindly keep this Card safely and bring it on your follow-up visits.

- धूम्रपान निषेध
- कूड़ा कर्कट केवल कूड़ेदान में ही डालें
- थूकिये नहीं
1. No Smoking
2. Use Dustbin
3. No Spitting

दिनांक - Date

उपचार - Treatment

7/10/23

Add

Syp omnacostol (1mg/ml)

0.5mg/kg

4ml OD

X 5 Days.

Syp Digene 1 tsp OD

- CST

- Flu on Thursday (ward 4A) 9:30 am

110
2

~~Dr. P. Sharma Chouda~~

13/10/23

→ Case to be taken up for elective procedure on later date

1/10 action URI -

currently sunny nose ⊕

Kindly review patient once URI resolves

1
Bend
SK

नेत्र ईश्वरीय सर्वश्रेष्ठ उपहार है जिनका मनुष्य जीवन में दान करना परमश्रेष्ठ है।

इनकी पूर्ण रक्षा कीजिए ताकि ये आपकी रक्षा कर सकें।

Eyes are God's most precious gift to man kind and eye donation is the most noble deed.

Take full care of them so that they can take care of you.

ब० रो० वि० कार्ड
O.P.D. Card

डा० राजेन्द्र प्रसाद नेत्र विज्ञान केन्द्र
अ० भा० आयु० सं०, नई दिल्ली - 110029

Dr. Rajendra Prasad Centre for Ophthalmic Sciences
A.I.I.M.S., New Delhi-110029



अनुभाग व दिन
Section and Day VI
बुधवार व शनिवार
Wednesday & Saturday

कमरा नंबर
Cabin No.

यू०एच०आई०डी० संख्या
UHID No. 107043941

आचार्य राधिका टंडन का एकक
Prof. Radhika Tandon's Unit

रोगी का नाम Name of the Patient	पुत्र/पुत्री/पत्नी S/D/W	लिंग Sex	आयु Age	पता Address
Aayansh Raj		M	14yr	
दिनांक DATE	निदान DIAGNOSIS			

उपचार Treatment

NRC Discussion By SR Unit-VI

(MRI of 13/9/23) (R) 20 mass 750% filling globe
 (CB not available) ← Can't comment on ON involvement.
 mild lid edema } preseptal
 No collection } No Iloextension.

Post Contact films
Unavailable

कृपया इस कार्ड को सुरक्षित रखें तथा अस्पताल में दिखाने के समय हर वक्त साथ लायें।

Kindly keep this Card safely and bring it on your follow-up visits.

- धूम्रपान निषेध 1. No Smoking
- कूड़ा कर्कट केवल कूड़ेदान में ही डालें 2. Use Dustbin
- थूकिये नहीं 3. No Spitting



सं. 1
NO. 1

बिहार सरकार
GOVERNMENT OF BIHAR
योजना और विकास विभाग
DEPARTMENT OF PLANNING AND DEVELOPMENT
SADAR HOSPITAL HAJIPUR
SADAR HOSPITAL HAJIPUR

फॉर्म-5
FORM-5



जन्म प्रमाण-पत्र
BIRTH CERTIFICATE

जन्म मृत्यु रजिस्ट्रेशन अधिनियम, 1969 की धारा 12 / 17 तथा बिहार जन्म मृत्यु रजिस्ट्रेशन नियम, 1999 के नियम 8(1) के अन्तर्गत जारी किया गया।

(ISSUED UNDER SECTION 12(17) OF THE REGISTRATION OF BIRTHS & DEATHS ACT, 1969 AND RULE 8(1) OF THE BIHAR REGISTRATION OF BIRTHS & DEATHS RULES 1999)

यह प्रमाणित किया जाता है निम्नलिखित सूचना जन्म के मूल अभिलेख से ली गई है कि SADAR HOSPITAL HAJIPUR तहसील हाजीपुर जिला वैशाली राज्य/संघ प्रदेश बिहार, भारत के रजिस्ट्रार में दर्जित है।

THIS IS TO CERTIFY THAT THE FOLLOWING INFORMATION HAS BEEN TAKEN FROM THE ORIGINAL RECORD OF BIRTH WHICH IS THE REGISTER FOR SADAR HOSPITAL HAJIPUR OF TAHSIL/BLOCK HAJIPUR OF DISTRICT VAISHALI OF STATE/UNION TERRITORY BIHAR, INDIA.

नाम / NAME: AYANSH RAJ

लिंग / SEX: पुरुष / MALE

जन्म तिथि / DATE OF BIRTH

जन्म स्थान / PLACE OF BIRTH

06-01-2022
SIXTH JANUARY TWO THOUSAND TWENTY TWO

SADAR HOSPITAL HAJIPUR

माता का नाम / NAME OF MOTHER
SONI KUMAR

पिता का नाम / NAME OF FATHER
DEEPAK KUMAR

माता का आडधार नंबर / MOTHER'S AADHAAR NO:

पिता का आडधार नंबर / FATHER'S AADHAAR NO:

जन्म के समय के माता-पिता का पता / ADDRESS OF PARENTS AT THE TIME OF BIRTH OF THE CHILD:

पिता-पिता का स्थायी पता / PERMANENT ADDRESS OF PARENTS:

SHAIKHOPUR, SANDAI BUZURG, VAISHALI, BIHAR

SHAIKHOPUR, SANDAI BUZURG, VAISHALI, BIHAR

पंजीकरण संख्या / REGISTRATION NUMBER
B 2022-10-90411-003109

पंजीकरण तिथि / DATE OF REGISTRATION:
03-04-2022

टिप्पणी / REMARKS (IF ANY):

जारी करने की तिथि / DATE OF ISSUE:
02-04-2022

जारी करने वाला अधिकारी / ISSUING AUTHORITY:

रजिस्ट्रार (जन्म-मृत्यु)
REGISTRAR (BIRTH & DEATH)
SADAR HOSPITAL HAJIPUR
SADAR HOSPITAL HAJIPUR

साक्षीतक एवं रजिस्ट्रार
(जन्म-मृत्यु)
असल का पता: ... (पिता का)

UPDATED ON
03-04-2022 03:59:50



* THIS IS A COMPUTER GENERATED CERTIFICATE *
* THE GOVT. OF INDIA VIDE CIRCULAR NO. 1912/2014 VS(CRS) DATED 27-JULY 2015 HAS APPROVED THIS CERTIFICATE AS A VALID LEGAL DOCUMENT FOR ALL OFFICIAL PURPOSES *
* प्रत्येक जन्म एवं मृत्यु का पंजीकरण सुनिश्चित करें / ENSURE REGISTRATION OF EVERY BIRTH AND DEATH *



दिनांक - Date

उपचार - Treatment

23/10/23

Csli Ocular Oncology Clinic
Wit VI

Significant ↓ in orbital cellulitis

Csli Prof. Dr. Anurag Chandra
Adv. Contin. Eld. Glycer. (3)
(R) Eld. Refresh tears (6)

Syp. ~~Omnacortil~~
(10mg/10ml) 5ml OD
ABF x 1 week
Syp. Augmentin 625mg
1.5ml TDS
Cefixim 200mg BD

~~Date of Admission - Review in Paeds Onc on Wednesday for
Sphincter Chemo as advised.
Review in Old Oncs Clinic #42B 2pm
for 2 cycles of Sphincter Chemo~~

RG

नेत्र ईश्वरीय सर्वश्रेष्ठ उपहार है जिनका मनुष्य जीवन में दान करना परमश्रेष्ठ है।
इनकी पूर्ण रक्षा कीजिए ताकि ये आपकी रक्षा कर सकें।

Eyes are God's most precious gift to man kind and eye donation is the most noble deed.

Take full care of them so that they can take care of you.



Centre of Excellence in Diagnostic Care
AN ISO 9001 : 2015 CERTIFIED CENTRE
Visit us : www.devimaging.com

Dev Imaging & Diagnostic Centre

(A Unit of Dev Institute of Nuclear Medicine Pvt. Ltd.)

DS 24/B, Digamber Place, Behind Lohia Nagar Petrol Pump, Kankarbagh, Patna - 800 020
Phones : 07544008111, 07544008112 E-mail : devnuclear_inst@rediffmail.com

Name :- Aayansh Raj
Pt's ID :- 13031
Refd By :- C/o I.G.I.M.S, Patna

Age/Sex :- 01Yrs/M
Date :- 13-Sep-23

MRI BRAIN

Technique :- On 1.5T magnet, the following pulse sequences were obtained- Axial - T1W, FLAIR, T2W, GRE, DWI. Coronal - T2W. Sag- T1W.

Clinical Details:-

The study reveals:-

Bilateral cerebral hemisphere appears normal in morphology and signal intensity on all pulse sequence.
No evidence of intracranial SOL, infarct or haemorrhage.
No restricted diffusion is seen on DWI.
Basal cisterns, sella and suprasellar region appear normal. No evidence of effacement is seen. There is no midline shift.
Bilateral basal ganglia and thalamus are normal.
Ventricular system reveal normal anatomical configuration.
Posterior fossa structures like brainstem, cerebellum, C.P. angle cistern and fourth ventricle are normal.
Major intracranial vessels reveal normal signal void on spin echo images.
7th and 8th nerve complexes appear normal.
Visualized cervical cord appears normal.
MRI orbit reported separately.

IMPRESSION:- Normal study of brain with no focal parenchymal lesion or abnormal signal changes.

Dr. Madhukar Dayal.
Consultant and Interventional
Radiologist. MD(AIIMS), DNB



Centre of Excellence in Diagnostic Care
AN ISO 9001 : 2015 CERTIFIED CENTRE
Visit us : www.devimaging.com

Dev Imaging & Diagnostic Centre

(A Unit of Dev Institute of Nuclear Medicine Pvt. Ltd.)

DS 24/B, Digamber Place, Behind Lohia Nagar Petrol Pump, Kankarbagh, Patna - 800 020
Phones : 07544008111, 07544008112 E-mail : devnuclear_inst@rediffmail.com

Name :- Aayansh Raj
Pt's ID :- 13031
Refd By :- C/o I.G.I.M.S, Patna

Age/Sex :- 01Yrs/M
Date :- 13-Sep-23

Thanks for referral.

MRI BILATERAL ORBIT

Technique :- On 1.5T magnet, the following pulse sequences were obtained- Axial - T1 fat sat, T2. Coronal - T1, T2. Sag- (along long axis of optic nerve) T2, T1 SPIR.

Clinical Details:-

The study reveals:-

The right eye ball shows T1 hyperintense content in the posterior chamber with few fine bands in the retro-lental location and shallow anterior chamber. Lobulated T2 hyperintense lesion is seen in the posterior chamber with microcystic areas within the lesion. The lesion measures ~ 17 x 12mm with normal optic nerve. No extra-scleral extension of the lesion.

Left eyeball is normal in contour with normal thickness of sclerocoroidal wall.

Bilateral optic nerve is normal in thickness, morphology, signal intensity with maintained subarachnoid space around nerve. No abnormal tortuosity or lesion seen in the optic nerve proper.

The nerve shows normal course in the retrobulbar intraconal, intracanalicular and chiasmatal pathway with no obvious bony or soft tissue compression at any site. No discontinuity of the optic nerve is seen.

Optic chiasma is normal in location with normal morphology and signal intensity.

Infundibulum, sellar and suprasellar region is normal.

Extraocular muscles are normal in size and signal intensity.

Periorbital fat pad with retroconal fat shows normal signal intensity.

Superior orbital vein, bilateral ICA show normal flow void.

The visualized retrochiasmatic optic pathway appears normal.

IMPRESSION:-

- Vitreal hemorrhage in right eye ball with few fine bands in the retro-lental location and lobulated T2 hyperintense lesion is seen in the posterior chamber with microcystic areas within the lesion. No extra-scleral extension of the lesion.

Advised contrast MRI for further characterization and to rule out retinoblastoma.

hpd

Dr. Madhukar Dayal.
Consultant and Interventional
Radiologist. MD(AIIMS), DNB.

Our Dedicated Nuclear Medicine Centre :

Nuclear Imaging & Therapy LLP

(A Unit of Dev Institute of Nuclear Medicine Pvt. Ltd.)

Road No. 2, Rajendra Nagar, Patna - 800 016 Ph.: 7033097571, 780899936

Kindly Note : This Report is not for Medico-Legal Purpose. Any technical or typing error can be rectified.

Anaesthesia EUA Record
Dr. Rajendra Prasad Centre for Ophthalmic Sciences
All India Institute of Medical Sciences, New Delhi-110029

Name Ayansh Age/Sex 11F Ward/Bed _____ Ht/Wt _____ CR.No. 107043741
 ASA Grade: (1) 2 3 4 5 E Diagnosis _____ Surgery _____ Ph. No. _____
 History & current drugs

Not significant

Prematurity / post gestational age / cyanosis / apnoea

Previous Anaesthesia Exposure & its complications:

Congenital Anomalies/Syndrome: Pediatric Airway

Airway examination: Mallampati Class _____ Teeth _____

Neck movements Retrognathia _____ High arched/cleft palate _____

Nasal Patency Facies _____ Tongue _____

Tonsils Intubation: simple/difficult _____

Respiratory System: Resp. Rate _____ Auscultation _____

Cardiovascular System: Heart rate _____ Pulse rate _____ Neck Veins _____

Precordial Thrill Heart Sounds Murmur Preop. SpO₂ _____

IV access:

Nervous System: MR / Delayed milestones / CP / Seizures WNL

Musculoskeletal system examination WNL

Investigations

Hb ESR TLC/DLC B.Urea S. Cr. Na/K Ca
B. Sugar F. PP R T.P/A/G OT/PT TFT
X-Ray Chest ECG
ECHO
CT Brain MRI
Others

Preanaesthetic Instructions :

		Premedication	
Drug	Dose	Route	Time

**Anaesthesiologist
(Name)**

Anaesthesia details :

pt shifted OT
PAC done, MPO adequate
26G IV cannula secured over @ hand
all std ASA monitors attached
I. $\text{preO}_2 + \text{sevo}$ $\xrightarrow{26G}$ mask
M : $\text{O}_2 + \text{N}_2\text{O} + \text{sevo}$
R : $100\% \text{O}_2$
Vitals stable
Procedure U/E

[Signature]
SRJA

MANAV SEWA HEALTH AND EDUCATION

Anaesthesia EUA Record
Dr. Rajendra Prasad Centre for Ophthalmic Sciences
All India Institute of Medical Sciences, New Delhi-110029

Name Ajayankh Raj Age/Sex 1.5y Ward/Bed _____
 ASA Grade : 1 2 3 4 5 E Diagnosis _____
 History & current drugs (N) birth & developmental w/ing Surgery EUA Ph. No. _____
 CR.No. 107043941
10643466
 last breath 5:00 am

NO URTI

Prematurity / post gestational age / cyanosis / apnea

Previous Anaesthesia Exposure & its complications :

Congenital Anomalies/Syndrome :

Airway examination : Mallampati Class _____

Teeth _____

Neck movements Retrognathia _____

High arched/cleft palate _____

Nasal Patency Facies _____

Tongue _____

Tonsils Intubation : simple/difficult _____

Respiratory System : Resp. Rate _____

Auscultation B/L NRS

Cardiovascular System : Heart rate _____

Pulse rate _____

Nack Veins _____

Precordial Thrill _____

Heart Sounds S1,2 (N)

Murmur Absent

Preop. SpO₂ _____

IV access :

Nervous System : MR / Delayed mile stones / CP / Seizures

Musculoskeletal system examination

Investigations

Hb	ESR	TLC/DLC	B.Urea	S. Cr.	Na/K	Ca
B. Sugar F.	PP	R	T.P/A/G	OT/PT	TFT	
X-Ray Chest			ECG			
ECHO						
CT Brain			MRI			
Others						

Preanaesthetic Instructions :

	Drug	Dose	Premedication Route	Time
- w/1	consent	by	parent	
- NPO	-	8hrs	Solids	
-	4hrs	Rf		

Anaesthesiologist
(Name)

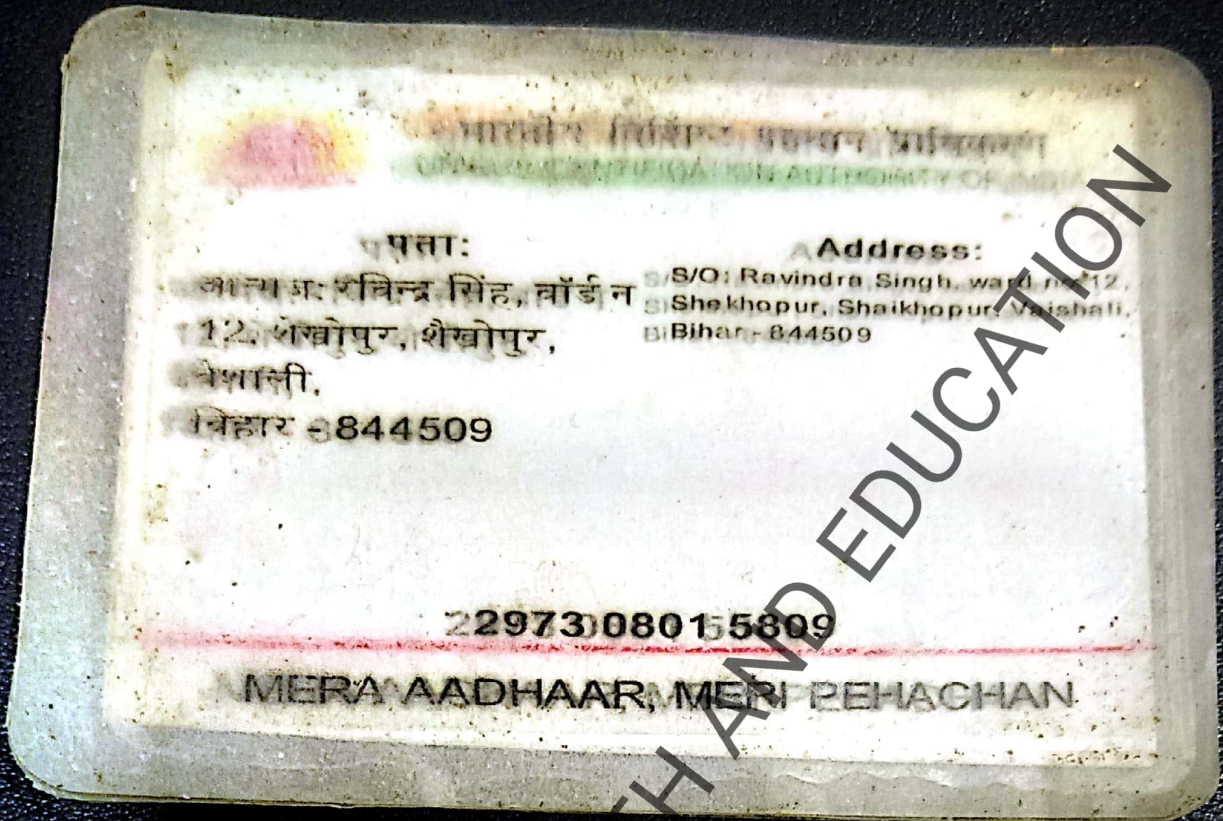
Anaesthesia details :

- P ₂	O ₂ + N ₂ O + Sev
M ₂	O ₂ + N ₂ O
R ₂	100% O ₂

Adv. - monitor vitals

- O₂ by fm @ 2L/min

↑
Pain
SR



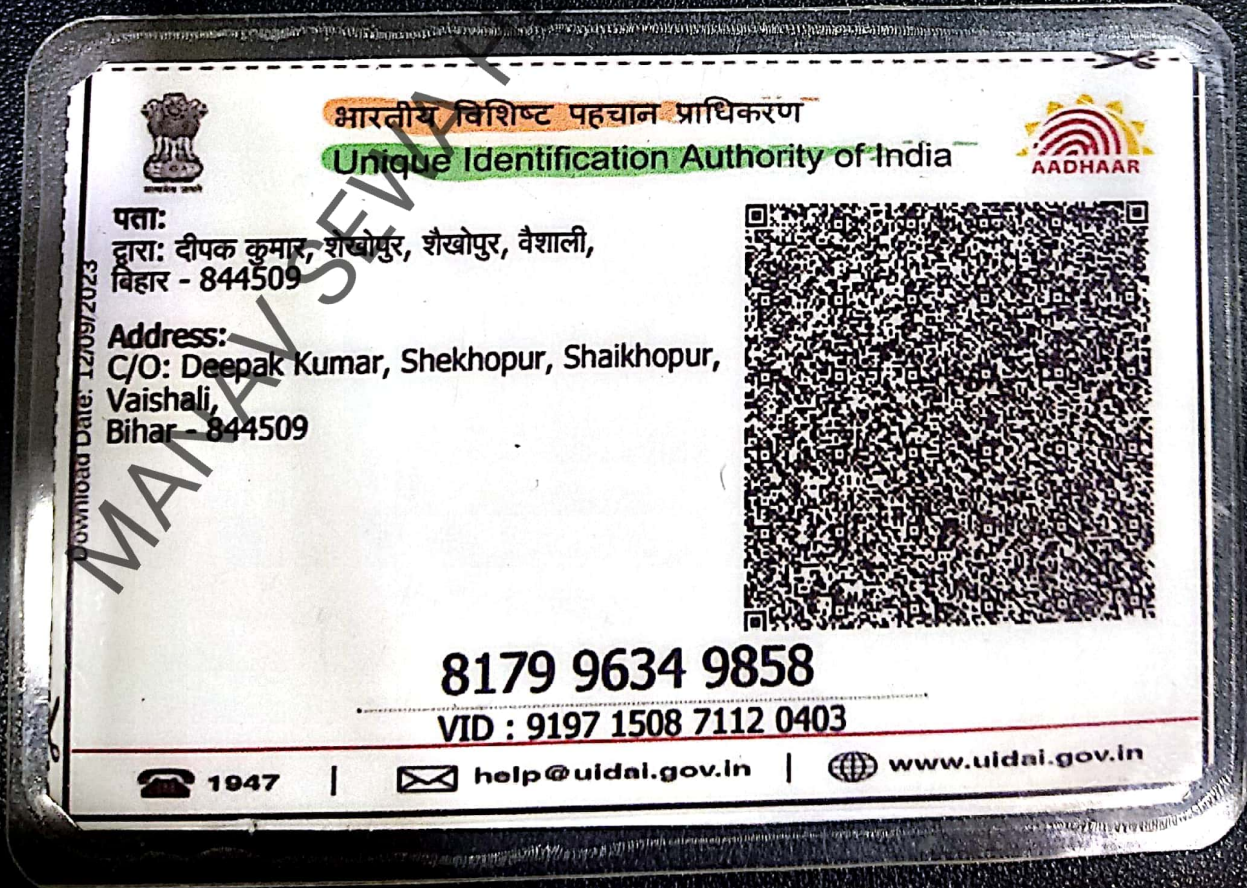भारतीय विशिष्ट पहचान प्राधिकरण
 Unique Identification Authority of India

पता: Address:
 S/O: Ravindra Singh, ward no 12,
 Shekhopur, Shaikhopur, Vaishali,
 Bihar-844509

पता: पता:
 S/O: Ravindra Singh, वॉर्ड नं 12,
 शेखोपुर, शेखोपुर,
 वैशाली,
 बिहार - 844509

22973080155809

MERA AADHAAR, MERI PEHACHAN




भारतीय विशिष्ट पहचान प्राधिकरण
 Unique Identification Authority of India



पता:
 द्वारा: दीपक कुमार, शेखोपुर, शेखोपुर, वैशाली,
 बिहार - 844509

Address:
 C/O: Deepak Kumar, Shekhopur, Shaikhopur,
 Vaishali,
 Bihar - 844509



8179 9634 9858

VID : 9197 1508 7112 0403

1947

help@uidai.gov.in

www.uidai.gov.in

भारत सरकार
दीपक कुमार
Deepak Kumar
जन्म तिथि/ DOB: 16/11/1994
पुरुष / MALE
2973 0801 5809
मेरा आधार, मेरी पहचान

भारत सरकार
Government of India
आधार
सोनी कुमारी
Soni Kumari
जन्म तिथि/DOB: 31/12/1998
महिला/ FEMALE
8179 9634 9858
VID : 9197 1508 7112 0403
मेरा आधार, मेरी पहचान

Issue Date: 15/11/2014



GAUTAM I CARE & HEARING AID CLINIC

F-130/4, Lower Ground Floor, Gautam Nagar, New Delhi - 110049 (Near Post Office)
Ph.: 011-49072333, +91-9560859333 Web: www.gautamcare.com

Quotation

Date

To,

Mr. Ajaysh Raj S/o - Mr. Deepak Kumar, Shekhpur
Dist. - Vaishali (Bihar)

As per examination of eye, I would like to offer
you customized eye for right eye

Details are mention below -

- Customized eye with extra shine & polishing (baby case)
- 3D customized eye


Amount - 16300/-

Note - This price is valid for 1 month only from this date.

AUTHORISED DEALERS OF



Contact Lenses
Bausch & Lomb


Disposable Contact Lenses


fastrack
move on

oticon
PEOPLE FIRST

ALPS • DANAVOX • ELKON • HEARWELL • OTICON • PHOLIPS • REXTON • WIDEX • SIEMENS HEARING AIDS